Review

Respiration

Respiration 2006;73:382–395
DOI: 10.1159/000091609

Received: September 26, 2005
Accepted: December 1, 2005
Published online: February 14, 2006

Pulmonary Fibrosis in Hermansky-Pudlak Syndrome

A Case Report and Review

Diane M. Pierson[c] Diana Ionescu[b] Gefei Qing[a] Abdullah M. Yonan[d] Kent Parkinson[e] Thomas C. Colby[f] Kevin Leslie[f]

[a]Department of Pathology, University of Manitoba, Winnipeg, and [b]Department of Pathology, University of British Columbia, Vancouver General Hospital, Vancouver, Canada; [c]Anatomical Pathology, Mayo Clinic, Rochester, Minn., Departments of [d]Pulmonary Medicine and [e]Pathology, Banner Thunderbird Medical Center, Glendale, Ariz., and [f]Anatomical Pathology, Mayo Clinic, Scottsdale, Ariz., USA

Key Words
Hermansky-Pudlak syndrome · Pulmonary fibrosis · Lung transplantation · Bleeding diathesis · Oculocutaneous albinism

Abstract
Hermansky-Pudlak syndrome (HPS) is a rare heterogeneously inherited autosomal recessive group of disorders presenting with oculocutaneous albinism, bleeding diathesis and pulmonary disease. HPS is thought to occur as a consequence of disturbed formation or trafficking of intracellular vesicles, most importantly, melanosomes, platelet dense granules and lysosomes. The latter finding, in particular, contributes much to the morbidity associated with the disease, as ceroid lipofuscin deposits in lysosomes affect many organ systems. This is especially problematic in the lungs where it is often associated with pulmonary fibrosis and premature death. Currently, there are 7 known HPS genes in humans. In the mouse, at least 16 known HPS genes produce HPS-mutant phenotypes. The HPS gene mutation is considered to be one of the most prevalent single-gene disorders in northwest Puerto Rico, home to the largest cohort of known patients. In HPS, interventions addressing the bleeding diathesis and pulmonary fibrosis are often disappointingly ineffectual. Pirfenidone, a novel compound with documented anti-inflammatory, antioxidant and antifibrotic effects, appears to hold promise in delaying or preventing fibrosis. To date, there has been one successful lung transplant performed on a patient with HPS. We present a patient with HPS and review the current literature on our understanding of this rare disorder.

Copyright © 2006 S. Karger AG, Basel

Hermansky-Pudlak syndrome (HPS) was first described in 1959 as a unique disorder occurring in 2 unrelated patients who presented with albinism, bleeding diathesis and pulmonary disease [1]. The syndrome is currently recognized as a heterogeneously inherited autosomal recessive group of disorders affecting humans and mutant mice. The latter were implicated in the early 1980s, when researchers proposed that non-allelic mutant mouse strains, demonstrating lightly pigmented coat color and bleeding tendencies, could serve as disease models [2]. There are at least 7 HPS subtypes in man, HPS1 through HPS7, with well over a dozen genes linked with its pathogenesis [3, 4].

HPS is thought to occur as a consequence of disturbed formation or trafficking of intracellular vesicles, most importantly, melanosomes, platelet dense granules and ly-

KARGER
Fax +41 61 306 12 34
E-Mail karger@karger.ch
www.karger.com

© 2006 S. Karger AG, Basel
0025–7931/06/0000–0000$23.50/0

Accessible online at:
www.karger.com/res

Dr. Diane M. Pierson
Anatomical Pathology
Mayo Clinic
Rochester, MN 14606 (USA)
Tel. +1 507 284 1196, Fax +1 507 284 1875, E-Mail pierson.diane@mayo.edu

Downloaded from http://karger.com/res/article-pdf/73/3/382/3508450/000091609.pdf by RWTH Aachen University user on 06 March 2026

sosomes resulting in the classic triad of oculocutaneous albinism, platelet storage pool deficiency, and lysosomal accumulation of ceroid lipofuscin [5–8]. The latter finding, in particular, contributes much to the morbidity associated with the disease, as ceroid deposition affects many organ systems and is especially problematic in the lungs where it is often associated with pulmonary fibrosis and premature death. We present a patient with HPS and review the current literature on our understanding of this rare disorder. Clinical recognition of HPS facilitates genetic counseling, aids in prognostication, directs medical management, and is critical given a significant risk for intraoperative hemorrhage.

Case Report

A 28-year-old man of Mexican descent presented with exertional dyspnea and chronic dry cough. He also complained of arthralgia and morning stiffness. Clubbing of the extremities was not present. He denied a history of fever, hemoptysis or smoking.

The patient's medical history was notable for albinism diagnosed in childhood. He also had nystagmus and decreased visual acuity, not completely corrected with eyeglasses for near-sightedness. He gave a history of frequent nose bleeds, easy bruising and several episodes of protracted hemorrhagic colitis commencing at the age of 17. A 32-year-old albino sister also had a history of ecchymosis, but no pulmonary symptomatology. A paternal 'great-great' grandmother was said to be albino, but any history of pulmonary disease and age of death were unknown. The family history was otherwise positive for diabetes mellitus and hypertension.

As far as the patient knew his father was of Mexican descent, originally from Mexico City, and was unrelated to his Mexican mother who was born in southwestern Texas. There were no other relatives similarly affected, including the patient's parents and 2 other siblings. The patient was married and childless. He worked as a laborer in a warehouse.

A chest radiograph was abnormal showing diffuse reticulonodular interstitial infiltrates. A follow-up high-resolution computed tomographic (CT) scan demonstrated extensive bilateral diffuse reticular opacities predominantly in the bases and right middle lobe, but also involving the lingual and anterior portions of the upper lobes (fig. 1). Pulmonary function tests showed a restrictive pattern. The patient underwent video-assisted thoracic surgery where minimal pleural effusion and mild pleural adhesions were noted. The lung parenchyma was pink and diffusely thickened. A wedge resection of the lingula was obtained for cultures and histopathologic evaluation. Cultures returned negative. Microscopic sections showed advanced lung remodeling distinguished by architectural distortion and fibrosis (fig. 2). Chronic inflammatory cells were numerous and peculiar patchy clusters of clear vacuolated cells were distinctive (fig. 3, 4). Dual staining with thyroid transcription factor (TTF) and CD68 (to identify type II pneumocytes and macrophages, respectively) confirmed that the clear cells comprised both of these cell types (fig. 5). A diagnosis of HPS was made.

By the age of 30, the patient's pulmonary status had progressively decompensated, with a requirement of low flow continuous oxygen supplementation. However, he was hopeful of becoming a lung transplant recipient. Unfortunately, he succumbed to his disease before that was made possible. His sister continues to be without pulmonary symptoms, but is considering enrollment in a clinical study investigating the use of pirfenidone, a novel compound reported to deliver anti-inflammatory, antioxidant and antifibrotic effects.

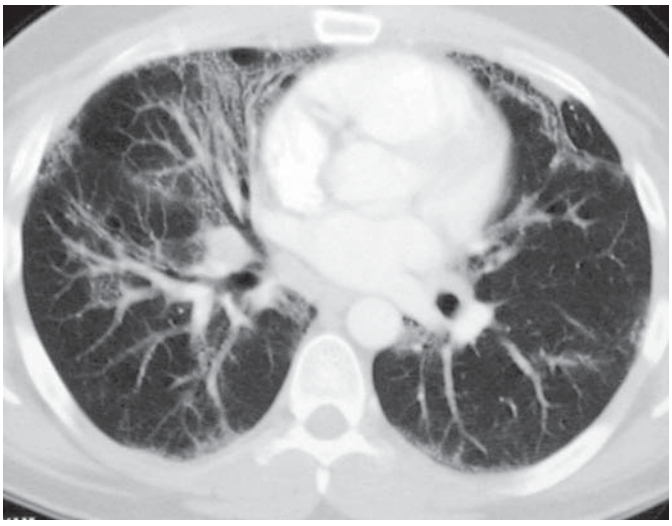

Fig. 1. The CT scan findings in HPS are dramatic and characterized by diffuse reticular opacities.

Table 1. Triad of classic findings in HPS

Findings
Oculocutaneous albinism
Bleeding diathesis
Pulmonary disease

Other significant findings include visual impairment and systemic ceroid lipofuscin deposition.

Discussion

Findings

HPS is a rare congenital disorder characterized by a triad of clinical manifestations including oculocutaneous albinism, bleeding diathesis and deposition of ceroid lipofuscin, a lipid-protein complex of unknown etiology [9]. Findings are listed in table 1. Seemingly disparate, these findings are presumably related to a common dys-

Downloaded from http://karger.com/res/article-pdf/73/3/382/3508450/000091609.pdf by RWTH Aachen University user on 06 March 2026

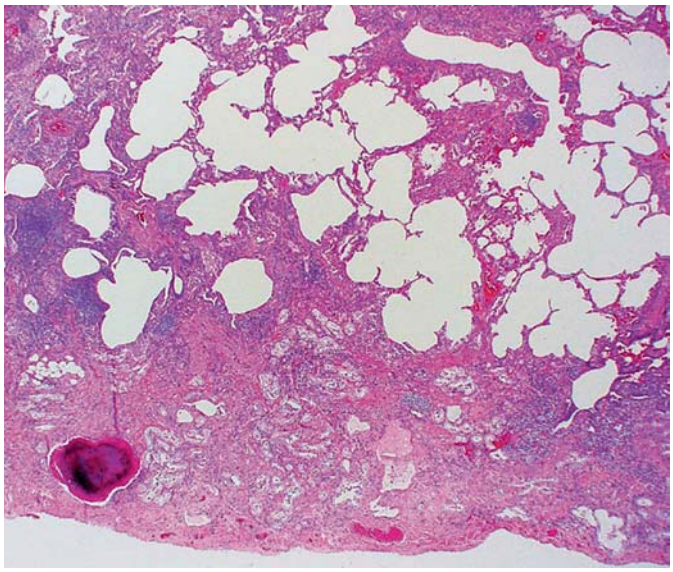

Fig. 2. Tissue sections show advanced lung remodeling with fibrosis, typically without an easily characterized distribution.

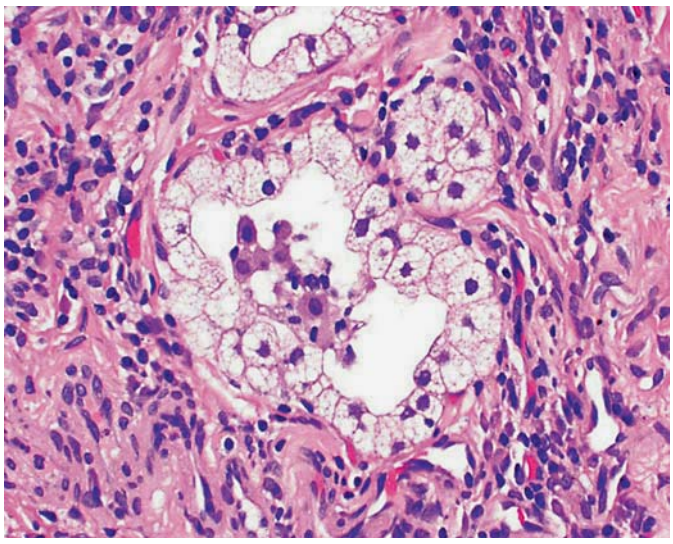

Fig. 4. Collections of foamy type II pneumocytes and alveolar histiocytes laden with ceroid, an insoluble lipoprotein substance, are distinctive in this example of HPS.

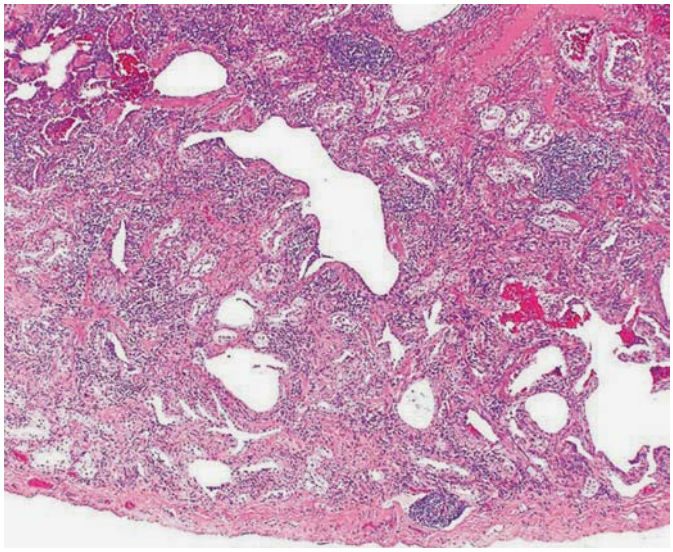

Fig. 3. At higher magnification, prominent clear vacuolated type II pneumocytes, patchy zones of fibrosis with an apparent bronchiolocentric distribution, and some evidence of constrictive bronchiolitis are seen.

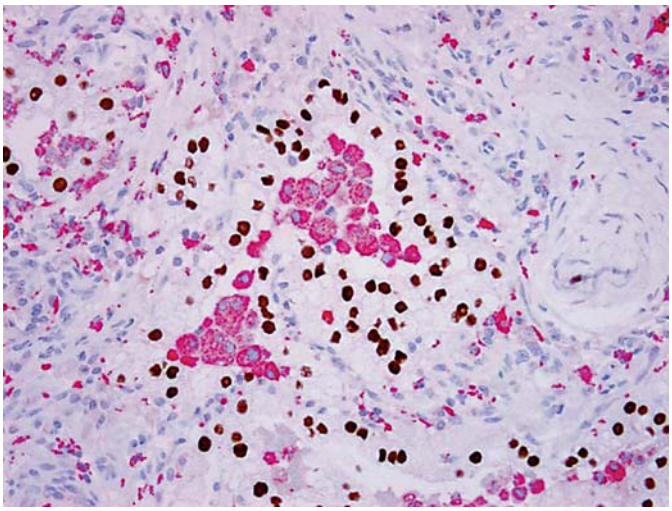

Fig. 5. Dual positive staining with TTF to identify type II pneumocytes and CD68 to validate histiocytic lineage show that the individual and clusters of clear vacuolated cells are comprised of both cell types.

function in biosynthesis of membrane-bound organelles: melanosomes in oculocutaneous albinism, platelet dense bodies in bleeding dysfunction, and lysosomes in ceroid lipofuscin deposition [6]. Melanosomes are cytoplasmic lysosomal-related organelles, most specific to melanocytes and retinal pigment epithelial cells that synthesize and store melanin pigment. Melanosomes can also be transferred to keratinocytes by poorly understood mechanisms. Platelet dense bodies, thought to be derived from lysosomal lineage, comprise a platelet-specific network of

Downloaded from http://karger.com/res/article-pdf/73/3/382/3508450/000091609.pdf by RWTH Aachen University user on 06 March 2026

membrane-bound organelles that regulate platelet activation and store serotonin, calcium, ATP, ADP, and pyrophosphates.

Lysosomes are membrane-bound organelles, housing at least 50 acid-dependant hydrolases that participate in intracellular degradation [10]. In HPS, there is variable impairment of the lysosomal system with subsequent ceroid deposition affecting many tissues of the body. This deposition is particularly toxic to the lungs, where it is associated with the highest morbidity and mortality. Apparently, not only are pulmonary macrophages dysfunctional, but there is also disruption of type II pneumocytes, which normally store surfactant in lamellar bodies [5]. Lamellar bodies, by histochemical and biochemical studies, are also considered to be lysosome-related organelles storing newly produced and recycled surfactant, thereby functioning in both intracellular secretory and endosomal pathways [11, 12]. Ultrastructural studies in HPS show type II pneumocytes distorted by giant lamellar bodies, reflecting the fusion of smaller organelles distended with surfactant.

The 'experiment in nature', that is HPS, is helpful in emphasizing our limited knowledge of the mechanisms involved in secretory and endocytic lysosomal pathways. Much of our understanding of these mechanisms has been gleaned from in-depth investigation of genetic screens done on yeast. In spite of this, some molecular components of human proteins required for functioning lysosyme and lysosyme-related organelles are not conserved in yeast and share no homology with any proteins of known function. Consequently, study of the protein products central to HPS have contributed greatly to the understanding of the obscure biogenesis of lysosomes and their related organelles [3, 13].

Interestingly, given their omnipresence, research suggests that the products of HPS genes may play more general functions than that of adjusting the biogenesis of melanosomes, platelet dense granules and lysosome secretions. Many lysosome-related organelles, in addition to the aforementioned, are now known to be derived from HPS gene associations. These include, but are not limited to, lytic granules of cytotoxic T-cell lymphocytes (CTL) and natural killer cells, mast cell basophilic granules, Weibel-Palade bodies of endothelial cells, and renin granules of juxtaglomerular cells [14, 15]. What role any of these organelles play in the pathogenesis of HPS, and to what extent, is unclear and under investigation. The only HPS subtype that has demonstrated any dysfunction of CTLs is HPS2, where lytic granule secretions have been documented to be decreased [16, 17].

Many studies using HPS animal mouse models have concentrated on melanocyte-specific proteins and their role in trafficking patterns in melanosome maturation. Analyzing the data from two studies, Nguyen et al. [4, 18] showed that HPS gene products were required at precise steps of melanosomal biogenesis in all but 1 of 15 HPS strains studied. A variety of abnormal findings in different subtypes were identified, including defective melanosomal maturation, melanin retention within melanosomes, and uptake of immature melanosomes by keratinocytes [4].

Population Genetics

The HPS gene mutation is considered to be one of the most prevalent single-gene disorders in northwest Puerto Rico, home to the largest cohort of known patients. In this region, HPS is thought to occur in about 1 in 1,800 persons with a carrier frequency estimated at 1 in 21 persons [19–21]. HPS in this locale personifies the founder effect, an evolutionary phenomenon, associated with rare alleles in populations that are relatively isolated, either geographically or culturally. The founder effect also appears to play a role in a remote area in central Puerto Rico and in an isolated mountain village in the Swiss Alps [22]. Given the geographical isolation of Puerto Rico, speculators have proposed a common ancestry. In fact, HPS in Puerto Rico and rare cases in Holland have been supposedly traced to a district of southern Spain. How the genes came to originate in Puerto Rico is unknown but possibilities include transfer by either British invasion in 1595, Dutch attackers in 1625, or even slave traders [22].

HPS is extremely rare in other nationalities, occurring with a prevalence of 1 in 500,000–1,000,000 persons [23, 24]. In fact, it is likely to occur in all ethnic groups, as sporadic cases have been described in a variety of backgrounds such as Sri Lankan, Japanese, and Finnish to name a few [5]. A case from Mexico has also been previously described [25]. In the United States, over 100 patients have been identified. This number is probably underestimated due to a generally low threshold of clinical suspicion. HPS should be considered in the differential diagnosis of any patient with diffuse lung disease and inflammatory bowel disease, especially in the setting of albinism and bleeding tendencies [23, 26].

Molecular Genetics

Currently, there are 7 known HPS genes in humans [8, 14, 27–30]. In the mouse, at least 16 known HPS genes produce HPS-mutant phenotypes, whereas 14 of these have been cloned with 7 of those orthologous to the

Downloaded from http://karger.com/res/article-pdf/73/3/382/3508450/000091609.pdf by RWTH Aachen University user on 06 March 2026

Table 2. HPS gene mutations in humans and rodent models

Gene symbol	Rodent model[1]	Human disease
HPS1	pale ear	HPS1
AP3B1	pearl	HPS2
HPS3	cocoa	HPS3
HPS4	light ear	HPS4
HPS5	ruby-eye 2	HPS5
HPS6	ruby-eye	HPS6
DTNBP1	sandy	HSP7
AP3D1	mocha	
PLDN	pallid	
MUTED	muted	unknown
CNO	cappuccino	
BLOC1S3	reduced pigmentation	
VPS33	buff	
RAB38	ruby (rat)	

[1] Mouse model unless otherwise specified.

Table 3. Overview of subtype characteristics of HPS

Human disease	Characteristic
HPS1	prevalent northwest Puerto Rico associated with severe pulmonary fibrosis rodent model shares features[1] with HPS4 rodent model
HPS2	mild immunodeficiency symptoms with HPS morphologic features
HPS3	prevalent central Puerto Rico rodent model shares features with HPS5 and HPS6 rodent models
HPS4	associated with severe pulmonary fibrosis rodent model shares features with HPS1 rodent model
HPS5	screen positive in a 3-year-old Turkish boy with HPS features lacks pulmonary symptoms to date rodent model shares features with HPS3 and HPS6 rodent models
HPS6	screen positive in a 39-year-old Belgian female lacks pulmonary symptoms to date rodent model shares features with HPS3 and HPS5 rodent models
HSP7	screen positive in a 48-year-old Portuguese woman pulmonary symptoms of exertional dyspnea; negative CT changes rodent model shares features with Pallid and Muted rodent models

[1] Rodent features include coat color and melanosome number and distribution.

known human genes [4, 29, 31–33]. The HPS gene mutations in humans and rodent models are listed in table 2. Human disease has not been clearly described in association with any of the remaining 7 mouse clones (Mocha, Pallid, Muted, Cappuccino, Reduced pigmentation, Buff, and Ruby-rat). The genes are lacking in the HPS code for proteins that function in organelle biogenesis and transport of lysosomes and lysosome-related organelles [4, 13, 15, 27].

Cloned mice are raised on an identical background control mouse (C57BL/6J). Therefore, coat color variation has functioned as a means for discriminating and directing investigation of melanosome development and transport, especially as it pertains to subtypes. Early researchers noted that several mouse clones shared similar coat color, suggesting stage-specific functions in protein complexes. Polypeptides known to be integral to the structure of at least three protein complexes identified as lacking in HPS are designated as 'biogenesis of lysosome-related organelles complexes' (BLOC-1, BLOC-2 and BLOC-3) [3]. Mutants within a given BLOC show similar pathology. For example, all subtypes that are BLOC-1 mutants demonstrate very lightly colored coat colors reflecting a marked reduction in melanosome number. Likewise, ultrastructural examination of retinal pigment from BLOC-2 mutants has not only revealed a decreased melanosome number, but also distinctive grouping of melanosomes. In addition, mutants of BLOC-3, besides displaying reduced melanosomes, are distinguished by macromelanosomes in the retinal pigment, which are most likely fused smaller melanosomes [27, 33, 34].

A simplistic overview of some features associated with different HPS subtypes follows. These features are delineated in table 3. The interested reader is encouraged to refer to some excellent review articles on the molecular interactions in HPS for more in-depth discussion [2, 14, 35].

HPS1 Subtype

The most common HPS gene, HPS1 located on chromosome 10, was identified in 1996 [28]. It has been found in well over 400 affected individuals from northwest Puerto Rico where it overwhelmingly presents with homozygosity for a 16-base pair duplication in exon 15 [19–21]. Conversely, a frameshift at codon 322 is frequently seen in Europeans. Additionally, at least 18 different HPS1 gene mutations have been identified in non-Puerto Ricans exampled by establishment of a splice site type in Japanese patients [30]. The HPS1 gene is thought to demonstrate locus heterogeneity, the phenomenon observed

Downloaded from http://karger.com/res/article-pdf/73/3/382/3508450/000091609.pdf by RWTH Aachen University user on 06 March 2026

when identical clinical symptoms in different patients are explained by defects at two or more genetic loci [36]. Phenotypic variation is also believed to result from different HPS1 frameshift mutations causing non-uniform polypeptide truncation and subsequent divergent subcellular function [28].

The mouse model for HPS1 is *'pale ear' (ep).* Interestingly, homozygous *ep* mutant mice show phenotypic features of both HPS and Chediak-Higashi syndrome (CHS), intimating a relationship between the two. Patients with CHS, who typically die at an early age, manifest with marked immune deficiency, partial oculocutanoeus albinism and bleeding dyscrasias secondary to abnormal intracellular protein transport. Huge granulocytic cytoplasmic granules, not seen in HPS, are a feature of CHS [37–39].

The HPS1 protein is comprised of 400 amino acids with a putative molecular weight of 79.3 kDa [8, 28]. In all probability, the HPS1 product, a transmembrane protein, serves as an important element of several cytoplasmic organelles. Its specific function, similar to most HPS subtype proteins, is unknown. Similar cellular mechanisms appear to play a role between HPS1 and HPS4 subtypes as mutant mice in both subtypes share indistinguishable coat colors and their protein products are known to be components of the BLOC-3 complex [40–42].

HPS1 patients characteristically develop severe pulmonary fibrosis, often commencing in their thirties. Colitis occurs in about 15% of the cases [43]. There do not appear to be reportable differences in clinical manifestations between HPS1 Puerto Rican versus HPS1 non-Puerto Rican patients [9].

HPS2 Subtype

The HPS2 subtype is unique for two reasons. First, mild immunodeficiency symptoms accompany its phenotype, and second, it is the only HPS subtype whose gene product has an identified function. First described in 1999, the HPS2 gene (AP3B1) is located on chromosome 5 and codes for a 140-kDa subunit (β3A) of adaptor complex 3, a protein mediating vesicle formation and trafficking [17, 44, 45]. The HPS2 mutant mouse analogue is *pearl.*

The adaptor complex 3 is a 'coat' protein situated in the cell membrane. It is a merged collection of four different peptides that participate in recruitment of other membrane elements to form a newly formed vesicle, such as a melanosome or platelet dense body. In the case of HPS2, it includes lysosomes from the immune system [46]. CTLs demonstrate disrupted microtubule-mediated transport of lytic granules to the immunological synapse resulting in disordered secretion. This results in notably enlarged and aberrantly distributed lytic granules, which are easily visualized with electron microscopy [5, 17].

Only 4 HPS2 patients have been reported. Features of oculocutaneous albinism and bleeding tendency were described, as well as recurrent respiratory tract and sinus infections. Pulmonary disease in these few cases was mild.

HPS3 Subtype

In 2001, the first report of the HPS3 mutation was published after investigation of a 6-family kindred from central Puerto Rico. It has since been documented in other populations. The mutation is a large deletion located on chromosome 3q24 comprising 17 exons. The protein product is 113.7 kDa and is composed of 1,004 amino acids, but with no specific known function. The mouse model for the HPS3 subtype is *cocoa* [7, 19]. The mouse mutant for HPS3 shares similar phenotypic features, such as coat color, with HPS5 and HPS6 mutants supporting a shared association with the BLOC-2 protein complex [34, 47, 48].

Patients with HPS3 mutations typically present with mild phenotypic features. In fact, a few have been mistakenly thought to have ocular albinism rather than oculocutaneous albinism [23, 49]. Given this element of decreased expressivity, clinical recognition of HPS in this subtype may be even more under-recognized than the already classic type, especially in non-Puerto Rican individuals.

HPS4 Subtype

'Discovery' of the HPS4 subtype in 2002 followed scrutinization of the HPS4 *light ear (le)* mouse mutant. Suspicion that *le* might have a human homolog stemmed from the fact that *le* mice were identical in phenotype to HPS1 *ep* mice, who had human HPS1 homologues. Besides sharing typical HPS morphological features, *le* and *ep* mice both possessed discernibly enlarged lysosomes in the kidneys. The *le/le*:*ep/ep* double homozygotes also had phenotypes that were no different than the two homozygous single mutants. These findings implied that HPS1 and HPS4 proteins operated in the same biologic pathway [30, 50].

Localization of the HPS4 gene to chromosome 22q11.2-q12.2 was undertaken. At least two possible spliced mRNA transcripts were found to originate from this region producing proteins with as of yet no known

Downloaded from http://karger.com/res/article-pdf/73/3/382/3508450/000091609.pdf by RWTH Aachen University user on 06 March 2026

function. Researchers were then able to successfully screen non-Puerto Rican patients with HPS phenotypes for HPS4 gene mutations [50].

HPS5 and HPS6 Subtypes

Capitalizing on HPS hypopigmented mice models, *ruby-eye 2 (ru2)* and *ruby-eye (ru),* and utilizing genetic mapping techniques, isolation of HPS5 and HPS6 genes was possible and reported in 2003 [51]. Subsequent screening of 20 non-Puerto Rican HPS patients whose subtypes were unknown yielded one 3-year-old Turkish boy with the HPS5 gene mutation on chromosome 11p15-p13 and one 39-year-old Belgian woman with the HPS6 gene mutation on chromosome 10q24.32 [34]. Both individuals presented with oculocutaneous albinism and bleeding dyscrasia, but no pulmonary symptomatology. Given these isolated cases and the young age of the HPS5 patient, extrapolations on a 'generalized' phenotype associated with either of these subtypes is not possible.

Further evidence that protein products of both HPS5 and HPS6 genes interact in a common pathway has been established from examination of *ru2/ru2* and *ru/ru* choroidal tissue. Nearly indistinguishable clumping of melanosomes suggests that these genes affect a closely related if not the same pathway. These subtypes also share a relationship with the HPS3 mouse mutant and the BLOC-2 protein product [34].

HPS7 Subtype

Study of the mouse mutant *Sandy* localized a mutation to chromosome 13, where an inframe deletion of the gene Dtnbp1 was found to cause loss of dysbindin expression. In this context, dysbindin, a component of the BLOC-1 complex, was further investigated and found to be integral to the trafficking of lysosome-related organelles [33]. Loss affected coat color, as well as platelet dense granule and melanosome biogenesis. This ubiquitous protein binds to α- and β-dystrobrevins, elements of the dystrophin-associated protein complex present in both muscle and non-muscle cells.

Screening for the human ortholog DTNBP1 to the mouse Dtnbp1 in 22 unrelated non-Puerto Rican HPS persons has yielded one 48-year-old Portuguese woman, who is the daughter of first cousins. She exhibits oculocutaneous albinism, bleeding tendencies, and mild exertional dyspnea. However, work-up with high-resolution CT scans of the chest at this stage of her life is normal [33].

Elements of HPS

Tyrosinase-Positive Oculocutaneous Albinism

A disruption in the integrity of melanosomes and the synthesis and storage site of pigments results in different degrees of tyrosinase-positive oculocutaneous albinism in HPS patients. Tyrosinase, the enzyme essential for the oxidation of tyrosine via dopa to dopaquinone in the pathway of melanin formation, is present, but not in the usual amounts. The difference between oculocutaneous albinism not associated with HPS and HPS is that the former only affects the make-up and mechanisms of melanosomes as lysosome-related organelles, while the latter involves more types of lysosome-related organelles [35]. Of the syndromes occurring in albinism, HPS occurs with the highest frequency [23]. HPS patients are particularly susceptible to solar damage with reports of melanoma, actinic keratoses, squamous and basal cell carcinomas in the literature. About 80% of HPS individuals have freckles or lentigines [27, 52, 53].

Partial albinism is not always recognized as such in HPS, with some patients presenting with dark hair and more obvious ocular albinism, while others are discerned by their conspicuous creamy white complexion and blonde to white hair [3]. Generally, skin coloring is a shade lighter than in non-affected family members [23]. The iris color is usually blue, but shades of green or brown have also been reported. Our patient's skin tone was similar to his affected sister's coloring; several shades lighter than the coloring of the other family members. Both our patient and his affected sister also displayed dark blonde hair and brown eyes.

Visual Impairment

All HPS patients have some type of visual impairment, as normal melanin production is mandatory for healthy retinal and neural development between the eye and brain. Ophthalmologic findings are quite variable, even in patients homozygous for the same mutation, and range from mild decreased acuity to legal blindness, commonly not ameliorated by corrective lenses [46]. Horizontal nystagmus is often the rule, but strabismus and other manifestations are common [49]. This was also the case with our patient who, although lacking strabismus, showed nystagmus with poor vision despite the use of eyeglasses.

Bleeding Diathesis

Not uncommonly, a striking symptom of HPS is a variable bleeding diathesis, which can present as ecchy-

Downloaded from http://karger.com/res/article-pdf/73/3/382/3508450/000091609.pdf by RWTH Aachen University user on 06 March 2026

mosis, epistaxis, gingival bleeding, menorrhagia, or postpartum bleeding, being a reflection of unbalanced dense body assemblage and function. Some degree of mucocutaneous hemorrhage has been reported in practically all HPS patients [54]. Notably, an estimated 40% of HPS patients are vulnerable to life-threatening hemorrhage with an approximate 10% supposedly succumbing to bleeding complications [55–57]. Not surprisingly then, severe anemia is a problem to young and old alike.

The bleeding diathesis stems from dysfunction occurring in the second phase of platelet aggregation, which is dependant on ATP, calcium and serotonin stored in dense bodies. In a hypopigmented patient, the current absolute prerequisite for a diagnosis of HPS is absence or marked diminishment in number or size of platelet dense bodies by electron microscopy, although in actual clinical practice, the combined presence of albinism and abnormal results of platelet aggregation studies usually serve as sufficient corroborating evidence of disease [23, 58]. The bleeding time is often prolonged in HPS, but the platelets, prothrombin and activated partial thromboplastin times are normal.

Ceroid Deposition

Ceroid, Latin for wax-like, is a complex chromolipid of unknown etiology that can, but does not always collect in organ systems. Brilliantly fluorescent under ultraviolet light, ceroid can also be identified as a minute, granular brown, acid-fast pigment [59]. Organs such as the lungs, intestines and kidneys of HPS patients often demonstrate variable degrees in severity of pulmonary fibrosis, granulomatous colitis, and rarely, renal failure, secondary to ceroid deposition [60]. Other sites of involvement include, but are not limited to, the bone marrow, heart, spleen, liver and large intestines [53]. Dolichols, isoprenoid compounds produced by the same metabolic route as cholesterol, are also present in the urinary sediment of affected individuals [61].

Inflammatory Bowel Disease

Our patient had a history of several episodes of hemorrhagic granulomatous colitis that first appeared at the age of 17. Patients with HPS not uncommonly display a Crohn-like colitis and do so at a younger age than pulmonary disease, usually between the ages of 12 and 30. A patient as young as 3 years old has even been described [62–64]. Most cases have been of Puerto Rican descent, perhaps reflective of the population investigated, and were as a group relatively resistant to medical intervention [64]. Approximately 13% of HPS patients die secondary to complications from this type of inflammatory disease [55].

Pulmonary Fibrosis

Ceroid, which accumulates in the lungs sporadically and slowly even in 'classic' Puerto Rican patients, is not crucial for a diagnosis of HPS, but primarily accounts for the significant associated morbidity. Pulmonary fibrosis, usually manifesting in the 3rd and 4th decades of life, accounts for premature death in 50% of HPS patients, generally by the 5th decade [46, 62]. HPS1 and HPS4 individuals show the greatest degree of involvement with an estimated 80% of HPS1 subtypes afflicted [7, 50]. However, studies evaluating pulmonary involvement in other subtypes are lacking so any conclusions should be interpreted with circumspection [60]. Interestingly, pulmonary findings are supposedly twice as common in females compared with males [59].

Pathogenesis underlying the pulmonary fibrosis of HPS is unclear. There is speculation that intracellular disruption of type II pneumocytes by ceroid triggers a cascade of inflammation, cytokine production and fibroblast proliferation, ultimately culminating with development of fibrosis. Animal mouse models, homozygously recessive for both HPS1 and HPS2 genes, synergistically display pathologic findings similar to the HPS human counterpart [31]. Type II pneumocytes normally store surfactant in organelles called lamellar bodies, but these mouse models showed 'giant lamellar body degeneration' with intracellular organelles demonstrating florid foamy degeneration of surfactant material aberrantly produced and secreted [12, 39, 44].

A substantial parenchymal inflammation is recognized in mutant mice and is hypothesized to play a key role in the development of pulmonary fibrosis and emphysema in humans [65]. Other mechanisms and factors, such as heightened apoptosis and action of metalloproteinase inhibitors, are also likely operatives given that disease progression does not always correlate with clinical measures of inflammation in humans [66]. Mutant mice show a marked increase in bronchoalveolar lavage macrophages mimicking the amplified number of macrophages in bronchoalveolar lavage fluid from HPS patients. In a study of patients with HPS by Nakatani et al. [12], numerous giant lamellar bodies were present in the macrophages and type II pneumocytes in lung specimens by ultrastructural exam. Moreover, phospholipid material in the vacuoles was weakly positive with antibodies directed against surfactant apoprotein by immunohistochemistry. In addition, lungs from HPS patients histori-

Downloaded from http://karger.com/res/article-pdf/73/3/382/3508450/000091609.pdf by RWTH Aachen University user on 06 March 2026

cally show increased autofluorescence, conjectured to be accrued ceroid deposition, as do mutant mice lungs, reflecting the most likely accumulation of surfactant and/or its derivatives in type II pneumocytes.

Our patient was not recognized as having HPS until microscopic sections of the lung biopsy were reviewed. A preponderance of abnormally vacuolated cells was present in a background of extensive pulmonary fibrosis. The conspicuous clear cells were found to be type II pneumocytes and macrophages, as verified by dual staining with TTF and CD68, which were seemingly distended with ceroidal material. Given the classic, albeit rare to actually encounter, histology and the patient's young age led us to believe that this was a case of possible HPS. Upon further clinical inquiry, we learned that the patient also had albino features and a bleeding tendency. He was subsequently confirmed to have HPS and treated with supportive care.

The relative early development of pulmonary fibrosis in HPS has some researchers postulating that repeated environmental or external insults, acting either alone or coupled with abnormal repair mechanisms, play a prominent role in the genetic disease predisposition. This hypothesis was tested in mice with the HPS1 gene mutation that did not develop pulmonary fibrosis overtly until stimulated to do so after intratracheal instillation of silica [67]. In this study, compared with controls, a marked increase in macrophages immunohistochemically staining for cathepsins L and B, potent fibrolytic enzymes found in macrophage lysosomes, was documented. However, despite the quantitative increase, a low ratio of enzymatic activity to antigen was measured. These findings suggest that the dysfunction was not in cathepsin transport into lysosomes, but was more related to the enzymatic activation process. Moreover, cathepsin L, which is associated with much greater collagen and elastin degradation activity compared with cathepsin B, was speculated to play the more dominant role as a common causative factor in pathogenesis [67, 68].

Our patient presented at a somewhat younger age of pulmonary fibrosis onset compared with other HPS patients. Supposedly, he had no contact with pet birds and had never used tobacco products. Unless his work in a warehouse made him unwittingly vulnerable to some type of air-borne contaminant, we had no clues as to why he would manifest with pulmonary symptoms in the 2nd decade of life.

Table 4. HPS treatment modalities

Disease	Treatment
Bleeding diathesis	platelet transfusion DDAVP levonorgestrel-releasing intrauterine system
Pulmonary disease	pirfenidone[1] lung transplantation[2] discourage smoking, pollutants

[1] Drug (anti-inflammatory antioxidant and antifibrotic effects) used in recently approved phase III clinical trials.
[2] One successful transplant to date.

Treatment

In HPS, interventions addressing at least two components of the disease process are critical, but often disappointingly ineffectual. First, bleeding with its subsequent complications should ideally be prevented or at least minimized. This is not always achieved satisfactorily. The second aspect, prevention and minimization of pulmonary fibrosis, is even more problematic and perplexing. Treatment options are listed in table 4.

Bleeding Diathesis

HPS, representative of a qualitative platelet defect disorder, is often treated with platelet transfusions and/or desmopressin acetate (DDAVP). This is standard intervention for many qualitative, as well as quantitative bleeding disorders, such as von Willebrand disease, hemophilia A, various platelet disorders and uremic bleeding [69, 70]. Unfortunately, indiscriminate platelet usage increases risk of exposure to infectious agents. Perhaps even more disconcerting is the probable chance of becoming platelet refractory secondary to alloimmunization associated with repeated blood product exposure.

DDAVP is a synthetic antidiuretic analogue used in the treatment of central diabetes insipidus. Its action is to reabsorb water in the renal tubules. DDAVP also affects a transient release of coagulant factor VIII complex, von Willebrand factor and tissue plasminogen activator from endothelial cell storage sites by poorly understood mechanisms. As such, the drug is often used for bleeding management in some of the aforementioned populations [70, 71]. Uncommon but known risks of DDAVP include water intoxication and hyponatremia [72].

Downloaded from http://karger.com/res/article-pdf/73/3/382/3508450/000091609.pdf by RWTH Aachen University user on 06 March 2026

Conflicting information on the effectiveness of DDAVP usage in HPS patients has been reported. While some found merit, others were disappointed [56, 73, 74]. Although testing with DDVAP prior to intervention has been recommended, at least 1 case demonstrates that effectiveness can be quite variable even within the same individual [55]. Another study, employing molecular characterization, showed that 15 of 19 Puerto Rican children with HPS1 gene mutation (present in >50% of Puerto Ricans with HPS) and 2 of 4 without HPS1 gene mutation failed to improve their bleeding times after test doses of DDAVP. Previous bleeding studies in Dutch and Belgian patients have been criticized for failing to identify mutation types, highlighting the complexity of determining effectual treatment [54, 73].

A novel approach to control bleeding in HPS patients with menorrhagia is the levonorgestrel-releasing intrauterine system. This product suppresses endometrial and spiral artery growth while concomitantly increasing capillary thrombosis. Benefits include effective contraception without systemic effects of progesterone and lack of required compliance [72]. Success has also been met with administration of recombinant activated factor VII in 1 reported case [69].

Pulmonary Fibrosis

As stated above, abnormal host response to healing tissue chronically insulted by ceroid deposition is the factor speculated to play the most prominent role in pulmonary architectural distortion. Refinement of this hypothesis recognizes that there is likely sequential injury to alveolar epithelial cells, as severity of giant lamellar body degeneration of type II pneumocytes correlates with interstitial inflammation [39]. Current treatment strategies with drugs such as corticosteroids, cyclophosphamide, azathioprine and cyclosporine generally fail to curtail this disease progression and often subject patients to a host of adverse effects, which include myelosuppression, oncogenesis and even pulmonary toxicity.

In general, to date, treatment of idiopathic pulmonary fibrosis and HPS, specifically, may even exacerbate the inevitable pulmonary insufficiency associated with disease [62, 75]. A data analysis of HPS patients in one study sorted two subpopulations, one group succumbing to death around the age of 40 and another progressing to demise within the following 2 decades. Individual variation of disease progression within subpopulations was also reported [62]. These findings highlight the challenge of attempting to evaluate the efficacy of treatment strategies in this somewhat diverse group given different HPS subtypes, variable genetic inflammatory responses, compliance issues, and individual superimposed environmental exposures. However, the group as a whole is still more discreet than the population of patients with the more generic disease of idiopathic pulmonary fibrosis.

Pirfenidone, a novel compound with documented anti-inflammatory, antioxidant and antifibrotic effects has had the advantage of being investigated in a select population of 21 adult HPS Puerto Rican patients, of whom 20 demonstrated homozygous HPS1 gene mutation. This was a randomized, placebo-controlled trial that employed the rate of change of pulmonary function values as the outcome measure. The participants were evaluated every 4 months for up to 44 months. Outcome data showed the pirfenidone group to have an approximate 8%/year slower decline of pulmonary function compared with a control group [62].

Pirfenidone has specifically been shown to minimize the production of collagen I and II and tumor necrosis factor-α, and inhibits the synthesis of extracellular matrix in animal mouse models [76–78]. In addition, it has been shown to lessen pulmonary fibrosis by modulating the fibroproliferative actions of transforming growth factor-β in cultured human fibroblasts [79]. Encouraging results have recently been reported from a double-blind, placebo-controlled study evaluating the treatment effect of pirfenidone in 107 patients with idiopathic pulmonary fibrosis. Preliminary findings showed that administration of pirfenidone enhanced vital capacity and precluded acute disease exacerbation in the intervention group throughout 9 months of follow-up. Acute exacerbation of idiopathic pulmonary fibrosis has been shown to portend a poor prognostic sign as these episodes have been shown to be associated with progressive respiratory decompensation and death in this population despite aggressive life support measures [80–82]. Given this fact, an independent data and safety monitoring board recommended that the pirfenidone study be aborted earlier than anticipated, as it was unethical to have the compound unavailable to control group participants [83]. Likewise, endpoints of the study could not be assessed adequately and final conclusions could not be drawn reliably. Adverse effects such as photosensitivity, vomiting, abnormal hepatic function, and facial paralysis were associated with drug usage, with photosensitivity being the most prevalent. However, those effects ceased or were mitigated by decreasing the dose or temporarily discontinuing the medication [83].

Pirfenidone appears to hold promise in delaying or preventing fibrosis, but its benefits in humans are not yet

Downloaded from http://karger.com/res/article-pdf/73/3/382/3508450/000091609.pdf by RWTH Aachen University user on 06 March 2026

fully known, pending development and results of ongoing clinical trials [84, 85]. Approval for a phase III drug trial to study the effects of pirfenidone has recently been granted. Although pirfenidone appears to slow pulmonary disease progression, it does not eradicate it completely. Most likely, this compound in combination with other drugs will prove to be more beneficial in controlling fibrosis associated with HPS than used alone [43].

To date, there has been one successful lung transplant performed on a patient with HPS, with at least 4 other HPS patients under consideration for the procedure [86]. Successful outcomes, by optimizing patient selection and providing for adequate hemostatic control during the surgical and postsurgical period, and awareness that transplantation is an achievable treatment goal will likely encourage management of HPS patients with this modality.

Ongoing development of safe and reliable vectors for gene therapy is also intriguing, and hopefully, normal gene delivery will be an option for HPS individuals in the not so distant future [14].

Medical and Genetic Counseling

An accurate diagnosis of HPS, especially of HPS1 subtypes, is beneficial in providing an opportunity for genetic counseling. Current treatment is supportive, as HPS is incurable. Ophthalmic evaluation is helpful in identifying visual disturbances. Patients may benefit from protective sunglasses, telescopic lenses, high-contrast reading materials, and font magnifiers. Knowledge of a hematologic disturbance may prevent complications associated with certain drugs such as aspirin. Avoidance of involvement in contact sports and recognition of a possible bleeding risk accompanying dental, obstetrical and surgical procedures is advisable. Dermatologic care to include skin protection education and monitoring for the development of skin lesions is also warranted. Evaluation and care of all body systems is not unreasonable, as ceroid deposition is often widespread. Our patient initially presented with arthralgias and morning stiffness. He was told that he had rheumatoid arthritis. As far as we know, joint involvement in HPS has not been reported, but may need to be investigated.

Information for patients and their families is available through the Hermansky-Pudlak Syndrome Network Inc. (http://www.hpsnetwork.org). This support group was founded by the mother of the 3-year-old non-Puerto Rican patient reported to present with Crohn-like colitis. The Hermansky-Pudlak Syndrome Network Inc. is a not for profit organization for individuals and families dealing with HPS and related disorders such as CHS. Their stated mission is to gather and disseminate information, promote awareness and research and provide support to its members [87].

Summary

We reported a case of pulmonary fibrosis in a young patient with HPS. Recognition of the existence of this rare disorder is imperative for provision of much-needed genetic counseling and supportive system-wide care. For those with debilitating pulmonary involvement, lung transplantation may be a treatment option. Although long-term outcome of any prophylactic pharmaceutical intervention is currently unclear, early trial results with pirfenidone, an anti-inflammatory, antioxidant and antifibrotic agent, appears to hold some promise in preventing or minimizing pulmonary fibrosis, either by itself or in combination with other drugs. Futuristically, dependable vectors for gene therapy may provide the means for HPS patients to benefit from normal gene delivery to disease-prone lungs. Lastly, HPS has and continues to serve as an invaluable and dynamic model for studying mechanisms involved in secretory lysosome functioning.

Downloaded from http://karger.com/res/article-pdf/73/3/382/3508450/000091609.pdf by RWTH Aachen University user on 06 March 2026

References

1 Hermansky F, Pudlak P: Albinism associated with hemorrhagic diathesis and unusual pigment reticular cells in the bone marrow: report of two cases with histochemical studies. Blood 1959;14:162–169.
2 Di Pietro SM, Dell'Angelica EC: The cell biology of Hermansky-Pudlak syndrome: recent advances. Traffic 2005;6:525–533.
3 Dell'Angelica EC: The building BLOC(k)s of lysosomes and related organelles. Curr Opin Cell Biol 2004;16:458–464.
4 Nguyen T, Wei ML: Characterization of melanosomes in murine Hermansky-Pudlak syndrome: mechanisms of hypopigmentation. J Invest Dermatol 2004;122:452–460.
5 Bachli EB, Brack T, Eppler E, Stallmach T, Trueb RM, Huizing M, Gahl WA: Hermansky-Pudlak syndrome type 4 in a patient from Sri Lanka with pulmonary fibrosis. Am J Med Genet 2004;127A:201–207.
6 Boissy RE, Richmond B, Huizing M, Helip-Wooley A, Zhao Y, Koshoffer A, Gahl WA: Melanocyte-specific proteins are aberrantly trafficked in melanocytes of Hermansky-Pudlak syndrome-type 3. Am J Pathol 2005;166:231–240.
7 Huizing M, Gahl WA: Disorders of vesicles of lysosomal lineage: the Hermansky-Pudlak syndromes. Curr Mol Med 2002;2:451–467.
8 Poletti V, Costabel U, Casoni GL, Bigliazzi C, Drent M, Olivieri D: Rare infiltrative lung diseases: a challenge for clinicians. Respiration 2004;71:431–443.
9 Hermos CR, Huizing M, Kaiser-Kupfer MI, Gahl WA: Hermansky-Pudlak syndrome type 1: gene organization, novel mutations, and clinical-molecular review of non-Puerto Rican cases. Hum Mutat 2002;20:482.
10 Dell'Angelica EC, Mullins C, Caplan S, Bonifacino JS: Lysosome-related organelles. FASEB J 2000;14:1265–1278.
11 Guttentag SH, Akhtar A, Tao JQ, Atochina E, Rusiniak ME, Swank RT, Bates SR: Defective surfactant secretion in a mouse model of Hermansky-Pudlak syndrome. Am J Respir Cell Mol Biol 2005;33:14–21.
12 Nakatani Y, Nakamura N, Sano J, Inayama Y, Kawano N, Yamanaka S, Miyagi Y, Nagashima Y, Ohbayashi C, Mizushima M, Manabe T, Kuroda M, Yokoi T, Matsubara O: Interstitial pneumonia in Hermansky-Pudlak syndrome: significance of florid foamy swelling/degeneration (giant lamellar body degeneration) of type-2 pneumocytes. Virchows Arch 2000;437:304–313.
13 Huizing M, Boissy RE, Gahl WA: Hermansky-Pudlak syndrome: vesicle formation from yeast to man. Pigment Cell Res 2002;15:405–419.
14 Li W, Rusiniak ME, Chintala S, Gautam R, Novak EK, Swank RT: Murine Hermansky-Pudlak syndrome genes: regulators of lysosome-related organelles. Bioessays 2004;26:616–628.
15 Marks MS, Seabra MC: The melanosome: membrane dynamics in black and white. Nat Rev Mol Cell Biol 2001;2:738–748.
16 Clark R, Griffiths GM: Lytic granules, secretory lysosomes and disease. Curr Opin Immunol 2003;15:516–521.
17 Clark RH, Stinchcombe JC, Day A, Blott E, Booth S, Bossi G, Hamblin T, Davies EG, Griffiths GM: Adaptor protein 3-dependent microtubule-mediated movement of lytic granules to the immunological synapse. Nat Immunol 2003;4:1111–1120.
18 Nguyen T, Novak EK, Kermani M, Fluhr J, Peters LL, Swank RT, Wei ML: Melanosome morphologies in murine models of Hermansky-Pudlak syndrome reflect blocks in organelle development. J Invest Dermatol 2002;119:1156–1164.
19 Anikster Y, Huizing M, White J, Shevchenko YO, Fitzpatrick DL, Touchman JW, Compton JG, Bale SJ, Swank RT, Gahl WA, Toro JR: Mutation of a new gene causes a unique form of Hermansky-Pudlak syndrome in a genetic isolate of central Puerto Rico. Nat Genet 2001;28:376–380.
20 Wildenberg SC, Oetting WS, Almodovar C, Krumwiede M, White JG, King RA: A gene causing Hermansky-Pudlak syndrome in a Puerto Rican population maps to chromosome 10q2. Am J Hum Genet 1995;57:755–765.
21 Witkop CJ, Nunez Babcock M, Rao GH, Gaudier F, Summers CG, Shanahan F, Harmon KR, Townsend D, Sedano HO, King RA, et al: Albinism and Hermansky-Pudlak syndrome in Puerto Rico. Bol Asoc Med P R 1990;82:333–339.
22 Krisp A, Hoffman R, Happle R, König A, Freyschmidt-Paul P: Hermansky-Pudlak syndrome. Eur J Dermatol 2001;11:372–373.
23 Izquierdo NJ, Royuela MA, Maumenee IH: Possible origins of the gene of Hermansky-Pudlak in Puerto Rico. P R Health Sci J 1993;12:147–148.
24 Poddar RK, Coley S, Pavord S: Hermansky-Pudlak syndrome in a pregnant patient. Br J Anaesth 2004;93:740–742.
25 Schallreuter KU, Frenk E, Wolfe LS, Witkop CJ, Wood JM: Hermansky-Pudlak syndrome in a Swiss population. Dermatology 1993;187:248–256.
26 Avila NA, Brantly M, Premkumar A, Huizing M, Dwyer A, Gahl WA: Hermansky-Pudlak syndrome: radiography and CT of the chest compared with pulmonary function tests and genetic studies. AJR Am J Roentgenol 2002;179:887–892.
27 Gwynn B, Martina JA, Bonifacino JS, Sviderskaya EV, Lamoreux ML, Bennett DC, Moriyama K, Huizing M, Helip-Wooley A, Gahl WA, Webb LS, Lambert AJ, Peters LL: Reduced pigmentation (rp), a mouse model of Hermansky-Pudlak syndrome, encodes a novel component of the BLOC-1 complex. Blood 2004;104:3181–3189.
28 Oh J, Bailin T, Fukai K, Feng GH, Ho L, Mao JI, Frenk E, Tamura N, Spritz RA: Positional cloning of a gene for Hermansky-Pudlak syndrome, a disorder of cytoplasmic organelles. Nat Genet 1996;14:300–306.
29 Oiso N, Riddle SR, Serikawa T, Kuramoto T, Spritz RA: The rat Ruby (R) locus is Rab38: identical mutations in Fawn-hooded and Tester-Moriyama rats derived from an ancestral Long Evans rat sub-strain. Mamm Genome 2004;15:307–314.
30 Suzuki T, Ito S, Inagaki K, Suzuki N, Tomita Y, Yoshino M, Hashimoto T: Investigation on the IVS5 +5G → A splice site mutation of HPS1 gene found in Japanese patients with Hermansky-Pudlak syndrome. J Dermatol Sci 2004;36:106–108.
31 Feng L, Novak EK, Hartnell LM, Bonifacino JS, Collinson LM, Swank RT: The Hermansky-Pudlak syndrome 1 (HPS1) and HPS2 genes independently contribute to the production and function of platelet dense granules, melanosomes, and lysosomes. Blood 2002;99:1651–1658.
32 Gardner JM, Wildenberg SC, Keiper NM, Novak EK, Rusiniak ME, Swank RT, Puri N, Finger JN, Hagiwara N, Lehman AL, Gales TL, Bayer ME, King RA, Brilliant MH: The mouse pale ear (ep) mutation is the homologue of human Hermansky-Pudlak syndrome. Proc Natl Acad Sci USA 1997;94:9238–9243.
33 Li W, Zhang Q, Oiso N, Novak EK, Gautam R, O'Brien EP, Tinsley CL, et al: Hermansky-Pudlak syndrome type 7 (HPS-7) results from mutant dysbindin, a member of the biogenesis of lysosome-related organelles complex 1 (BLOC-1). Nat Genet 2003;35:84–89.
34 Zhang Q, Zhao B, Li W, Oiso N, Novak EK, Rusiniak ME, Gautam R, Chintala S, O'Brien EP, Zhang Y, Roe BA, Elliott RW, Eicher EM, Liang P, Kratz C, Legius E, Spritz RA, O'Sullivan TN, Copeland NG, Jenkins NA, Swank RT: Ru2 and Ru encode mouse orthologs of the genes mutated in human Hermansky-Pudlak syndrome types 5 and 6. Nat Genet 2003;33:145–153.
35 Hearing VJ: Biogenesis of pigment granules: a sensitive way to regulate melanocyte function. J Dermatol Sci 2005;37:3–14.
36 Hazelwood S, Shotelersuk V, Wildenberg SC, Chen D, Iwata F, Kaiser-Kupfer MI, White JG, King RA, Gahl WA: Evidence for locus heterogeneity in Puerto Ricans with Hermansky-Pudlak syndrome. Am J Hum Genet 1997;61:1088–1094.
37 Introne W, Boissy RE, Gahl WA: Clinical, molecular, and cell biological aspects of Chediak-Higashi syndrome. Mol Genet Metab 1999;68:283–303.
38 Nowicki R, Szarmach H: Chediak-Higashi syndrome; in James WD, Elston DM (eds): eMedicine Dermatology. St. Petersburg, eMedicine Corporation, 1999.

Downloaded from http://karger.com/res/article-pdf/73/3/382/3508450/000091609.pdf by RWTH Aachen University user on 06 March 2026

39 Tang X, Yamanaka S, Miyagi Y, Nagashima Y, Nakatani Y: Lung pathology of pale ear mouse (model of Hermansky-Pudlak syndrome 1) and beige mouse (model of Chediak-Higashi syndrome): severity of giant lamellar body degeneration of type II pneumocytes correlates with interstitial inflammation. Pathol Int 2005;55:137–143.
40 Chiang PW, Oiso N, Gautam R, Suzuki T, Swank RT, Spritz RA: The Hermansky-Pudlak syndrome 1 (HPS1) and HPS4 proteins are components of two complexes, BLOC-3 and BLOC-4, involved in the biogenesis of lysosome-related organelles. J Biol Chem 2003; 278:20332–20337.
41 Martina JA, Moriyama K, Bonifacino JS: BLOC-3, a protein complex containing the Hermansky-Pudlak syndrome gene products HPS1 and HPS4. J Biol Chem 2003;278: 29376–29384.
42 Nazarian R, Falcon-Perez JM, Dell'Angelica EC: Biogenesis of lysosome-related organelles complex 3 (BLOC-3): a complex containing the Hermansky-Pudlak syndrome (HPS) proteins HPS1 and HPS4. Proc Natl Acad Sci USA 2003;100:8770–8775.
43 Gahl WA, Brantly M, Kaiser-Kupfer MI, Iwata F, Hazelwood S, Shotelersuk V, Duffy LF, Kuehl EM, Troendle J, Bernardini I: Genetic defects and clinical characteristics of patients with a form of oculocutaneous albinism (Hermansky-Pudlak syndrome). N Engl J Med 1998;338:1258–1264.
44 Lyerla TA, Rusiniak ME, Borchers M, Jahreis G, Tan J, Ohtake P, Novak EK, Swank RT: Aberrant lung structure, composition, and function in a murine model of Hermansky-Pudlak syndrome. Am J Physiol Lung Cell Mol Physiol 2003;285:L643–L653.
45 Dell'Angelica EC, Shotelersuk V, Aguilar RC, Gahl WA, Bonifacino JS: Altered trafficking of lysosomal proteins in Hermansky-Pudlak syndrome due to mutations in the beta 3A subunit of the AP-3 adaptor. Mol Cell 1999;3:11–21.
46 Shotelersuk V, Dell'Angelica EC, Hartnell L, Bonifacino JS, Gahl WA: A new variant of Hermansky-Pudlak syndrome due to mutations in a gene responsible for vesicle formation. Am J Med 2000;108:423–427.
47 Gautam R, Chintala S, Li W, Zhang Z, Tan J, et al: The Hermansky-Pudlak syndrome 3 (cocoa) protein is a component of the biogenesis of lysosome-related organelles complex-2 (BLOC-2). J Biol Chem 2004;279:12935–12942.
48 Di Pietro Sm, Falcon-Perez JM, Dell'Angelica EC: Characterization of BLOC-2, a complex containing the Hermansky-Pudlak syndrome proteins HPS3, HPS5 and HPS6. Traffic 2004; 5:276–283.
49 Tsilou ET, Rubin BI, Reed GF, McCain L, Huizing M, White J, Kaiser-Kupfer MI, Gahl W: Milder ocular findings in Hermansky-Pudlak syndrome type 3 compared with Hermansky-Pudlak syndrome type 1. Ophthalmology 2004;111:1599–1603.
50 Anderson PD, Huizing M, Claassen DA, White J, Gahl WA: Hermansky-Pudlak syndrome type 4 (HPS-4): clinical and molecular characteristics. Hum Genet 2003;113:10–17.
51 Huizing M, Hess R, Dorward H, Claassen DA, Helip-Wooley A, Kleta R, Kaiser-Kupfer MI, White JG, Gahl WA: Cellular, molecular and clinical characterization of patients with Hermansky-Pudlak syndrome type 5. Traffic 2004; 5:711–722.
52 Perry PK, Silverberg NB: Cutaneous malignancy in albinism. Cutis 2001;67:427–430.
53 Shotelersuk V, Gahl WA: Hermansky-Pudlak syndrome: models for intracellular vesicle formation. Mol Genet Metab 1998;65:85–96.
54 Cordova A, Barrios NJ, Ortiz I, Rivera E, Cadilla C, Santiago-Borrero PJ: Poor response to desmopressin acetate (DDAVP) in children with Hermansky-Pudlak syndrome. Pediatr Blood Cancer 2005;44:51–54.
55 Scheinfeld NS, Johnson AM: Hermansky-Pudlak syndrome. E-medicine, updated October 11, 2004.
56 Zatik J, Poka R, Borsos A, Pfliegler G: Variable response of Hermansky-Pudlak syndrome to prophylactic administration of 1-desamino 8D-arginine in subsequent pregnancies. Eur J Obstet Gynecol Reprod Biol 2002;104:165–166.
57 Teitel JM: Unexpected bleeding disorders: algorithm for approach to therapy. Clin Lab Haematol 2000;22(suppl 1):26–9; discussion 30–32.
58 Witkop CJ, Krumwiede M, Sedano H, White JG: Reliability of absent platelet dense bodies as a diagnostic criterion for Hermansky-Pudlak syndrome. Am J Hematol 1987;26:305–311.
59 Parker MS, Rosado Shipley W, de Christenson ML, Slutzker AD, Carroll FE, Worrell JA, White JG: The Hermansky-Pudlak syndrome. Ann Diagn Pathol 1997;1:99–103.
60 Brantly M, Avila NA, Shotelersuk V, Lucero C, Huizing M, Gahl WA: Pulmonary function and high-resolution CT findings in patients with an inherited form of pulmonary fibrosis, Hermansky-Pudlak syndrome, due to mutations in HPS-1. Chest 2000;117:129–136.
61 Witkop CJ Jr, Wolfe LS, Cal SX, White JG, Townsend D, Keenan KM: Elevated urinary dolichol excretion in the Hermansky-Pudlak syndrome. Indicator of lysosomal dysfunction. Am J Med 1987;82:463–470.
62 Gahl WA, Brantly M, Troendle J, Avila NA, Padua A, Montalvo C, Cardona H, Calis KA, Gochuico B: Effect of pirfenidone on the pulmonary fibrosis of Hermansky-Pudlak syndrome. Mol Genet Metab 2002;76:234–242.
63 Schinella RA, Greco MA, Cobert BL, Denmark LW, Cox RP: Hermansky-Pudlak syndrome with granulomatous colitis. Ann Intern Med 1980;92:20–23.
64 Mahadeo R, Markowitz J, Fisher S, Daum F: Hermansky-Pudlak syndrome with granulomatous colitis in children. J Pediatr 1991;118: 904–906.
65 Marshall RP, McAnulty RJ, Laurent GJ: The pathogenesis of pulmonary fibrosis: is there a fibrosis gene? Int J Biochem Cell Biol 1997;29: 107–120.
66 Cook DN, Brass DM, Schwartz DA: A matrix for new ideas in pulmonary fibrosis. Am J Respir Cell Mol Biol 2002;27:122–124.
67 Yoshioka Y, Kumasaka T, Ishidoh K, Kominami E, Mitani K, Hosokawa Y, Fukuchi Y: Inflammatory response and cathepsins in silica-exposed Hermansky-Pudlak syndrome model pale ear mice. Pathol Int 2004;54:322–331.
68 Ivy GO, Kanai S, Ohta M, Smith G, Sato Y, Kobayashi M, Kitani K: Lipofuscin-like substances accumulate rapidly in brain, retina and internal organs with cysteine protease inhibition. Adv Exp Med Biol 1989;266:31–45; discussion 45–47.
69 del Pozo Pozo AI, Jimenez-Yuste V, Villar A, Quintana M, Hernandez-Navarro F: Successful thyroidectomy in a patient with Hermansky-Pudlak syndrome treated with recombinant activated factor VII and platelet concentrates. Blood Coagul Fibrinolysis 2002; 13:551–553.
70 Kaufmann JE, Vischer UM: Cellular mechanisms of the hemostatic effects of desmopressin (DDAVP). J Thromb Haemost 2003;1: 682–689.
71 Teitel JM: Unexpected bleeding disorders: algorithm for approach to therapy. Clin Lab Haematol 2000;22(suppl 1):26–29; discussion 30–32.
72 Kingman CE, Kadir RA, Lee CA, Economides DL: The use of levonorgestrel-releasing intrauterine system for treatment of menorrhagia in women with inherited bleeding disorders. BJOG 2004;111:1425–1428.
73 Van Dorp DB, Wijermans PW, Meire F, Vrensen G: The Hermansky-Pudlak syndrome. Variable reaction to 1-desamino-8D-arginine vasopressin for correction of the bleeding time. Ophthalmic Paediatr Genet 1990;11:237–244.
74 Wijermans PW, van Dorp DB: Hermansky-Pudlak syndrome: correction of bleeding time by 1-desamino-8D-arginine vasopressin. Am J Hematol 1989;30:154–157.
75 Selman M, Thannickal VJ, Pardo A, Zisman DA, Martinez FJ, Lynch JP 3rd: Idiopathic pulmonary fibrosis: pathogenesis and therapeutic approaches. Drugs 2004;64:405–430.
76 Cain WC, Stuart RW, Lefkowitz DL, Starnes JD, Margolin S, Lefkowitz SS: Inhibition of tumor necrosis factor and subsequent endotoxin shock by pirfenidone. Int J Immunopharmacol 1998;20:685–695.
77 Iyer SN, Gurujeyalakshmi G, Giri SN: Effects of pirfenidone on transforming growth factor-beta gene expression at the transcriptional level in bleomycin hamster model of lung fibrosis. J Pharmacol Exp Ther 1999;291:367–373.
78 Gurujeyalakshmi G, Hollinger MA, Giri SN: Pirfenidone inhibits PDGF isoforms in bleomycin hamster model of lung fibrosis at the translational level. Am J Physiol 1999;276: L311–L318.

Downloaded from http://karger.com/res/article-pdf/73/3/382/3508450/000091609.pdf by RWTH Aachen University user on 06 March 2026

79 Kaneko M, Inoue H, Nakazawa R, Azuma N, Suzuki M, Yamauchi S, Margolin SB, Tsubota K, Saito I: Pirfenidone induces intercellular adhesion molecule-1 (ICAM-1) down-regulation on cultured human synovial fibroblasts. Clin Exp Immunol 1998;113:72–76.
80 Akira M, Hamada H, Sakatani M, Kobayashi C, Nishioka M, Yamamoto S: CT findings during phase of accelerated deterioration in patients with idiopathic pulmonary fibrosis. AJR Am J Roentgenol 1997;168:79–83.
81 Kondoh Y, Taniguchi H, Yokoi T, Suzuki R, Suzuki K, Noda Y, Ogawa K, Kato T, Mori T, Kaneko M, Takagi K: Acute exacerbation in idiopathic pulmonary fibrosis. Analysis of clinical and pathologic findings in three cases. Chest 1993;103:1808–1812.
82 Raghu G, Brown KK, Bradford WZ, Starko K, Noble PW, Schwartz DA, King TE Jr: Idiopathic Pulmonary Fibrosis Study Group. A placebo-controlled trial of interferon gamma-1b in patients with idiopathic pulmonary fibrosis. N Engl J Med 2004;350:125–133.
83 Azuma A: Shared mechanisms of lung injury and subsequent fibrosis: role of surfactant proteins in the pathogenesis of interstitial pneumonia in Hermansky-Pudlak syndrome. Intern Med 2005;44:529–530.
84 Lasky J: Pirfenidone. IDrugs 2004;7:166–172.
85 McKane BW, Fernandez F, Narayanan K, Marshbank S, Margolin SB, Jendrisak M, Mohanakumar T: Pirfenidone inhibits obliterative airway disease in a murine heterotopic tracheal transplant model. Transplantation 2004;77:664–669.
86 Padilla M: Medical Director, Lung Transplantation Program Director, ILD/Advanced Lung Disease Program, Mount Sinai Medical Center, New York, N.Y. Personal correspondence.
87 Appel D: Founder, Hermansky-Pudlak Syndrome Network Inc., Long Island, N.Y. Personal correspondence.

Downloaded from http://karger.com/res/article-pdf/73/3/382/3508450/000091609.pdf by RWTH Aachen University user on 06 March 2026